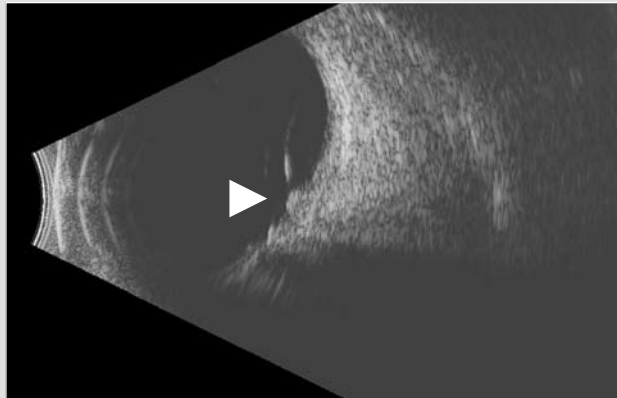
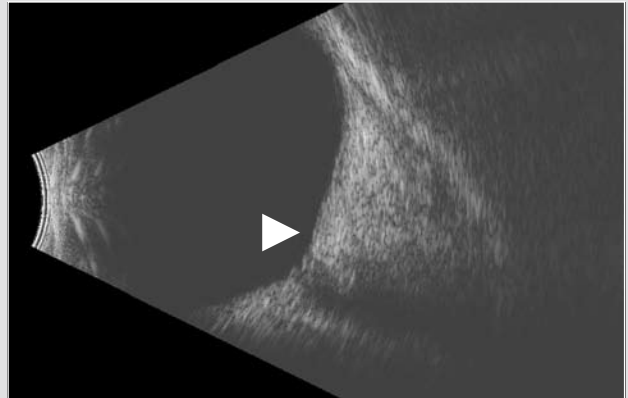


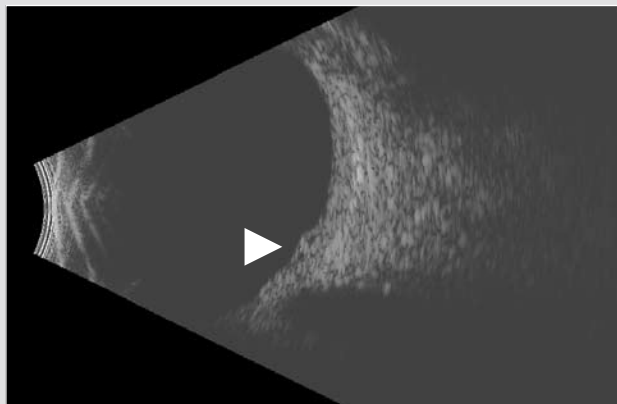
CASE STUDY THREE: **10 MHz B-Scan | Macular Pathology**



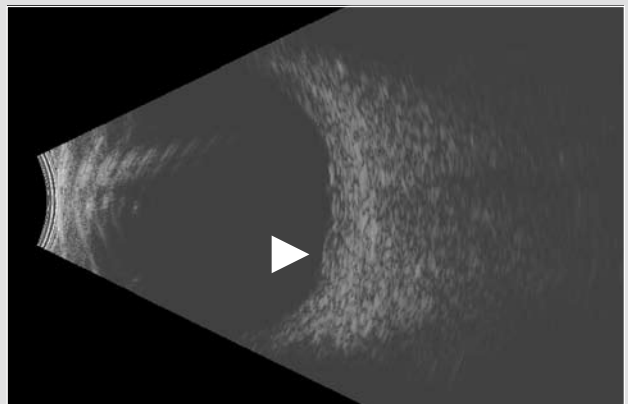
**CME caused by Vitreo Macular Traction Syndrome**  
(Longitudinal Macula View) Posterior hyaloid inserts at nerve, fovea and equator



**CME with no Vitreous Traction** (Longitudinal Macula View)  
Extensive edema altering globe contour; note optic cup



**CRVO with Double Macular Cyst** (Longitudinal Macula View)  
Central Retinal Vein Occlusion



**CRVO with Double Macular Cyst** (Vertical Macula View)  
Central Retinal Vein Occlusion

**Headquarters**

82 Gilbert Street  
Adelaide, SA, 5000 AUSTRALIA  
+61 8 8104 5200

**Japan**

4-3-7 Miyahara 4F, Yodogawa-ku  
Osaka 532-0003 JAPAN  
+81 6 6396 2250

**USA**

7138 Shady Oak Road  
Minneapolis, MN, 55344 USA  
1 800 824 7444

**Europe Support Center**

108, avenue Marx Dormoy  
63000 Clermont-Ferrand FRANCE  
+33 4 73 34 18 55