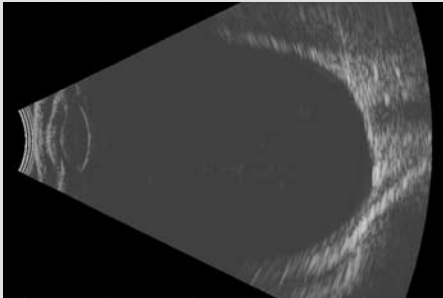
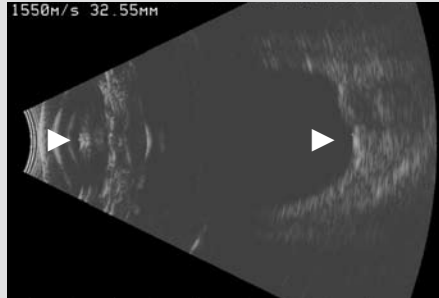


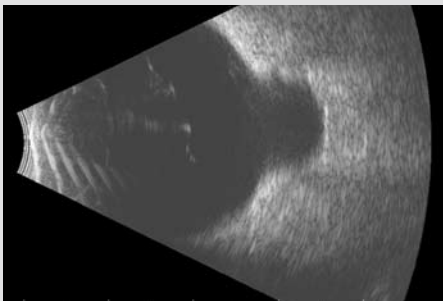
CASE STUDY FOUR: 10 MHz A-Scan and B-Scan | Staphyloma




40+ mm Eye
(Horizontal Axial View)



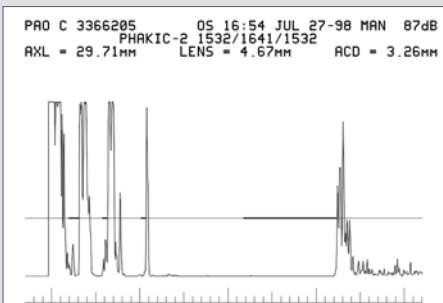
32+ mm Eye with Disk Edema (Method 2)
(Horizontal Axial View)



Unusual Globe Shape
(Horizontal Posterior View)



29+ mm Eye (Method 2)
(Horizontal Axial View)



Left: Measurement of Staphylomatous Eye Immersion Axial Length A-Scan for measurement of Axial Length.

Case Studies in Globe Contour

Axial Length Measurement of Staphyloma: Method 1

- 1 Perform immersion biometry, maximize double-peaked cornea and lens echoes. Document measurements of ACD at 1532 m/s for Aqueous and Lens Thickness @ 1641 m/s for crystalline lens.
- 2 Perform horizontal, axial B-Scan and center posterior lens and macula. Measure from Lens to Macula using velocity of 1532 m/s for Vitreous.
- 3 Add ACD and Lens from A-scan to Vitreous length from B-Scan to obtain Axial Length.
- 4 Repeat B-Scan and Vitreous measurement for added accuracy.

Axial Length Measurement of Staphyloma: Method 2

- 1 Perform immersion biometry, maximize double-peaked cornea, lens, and retinal echoes.
- 2 On the open globe using copious Tear Gel, perform horizontal, axial B-Scan and center double echo from cornea, posterior lens, and macula region. Measure from Anterior Cornea to Macula using velocity of 1550 m/s for an average velocity measurement.
- 3 Compare Axial Length measurements between the A-Scan and B-Scan.
- 4 Repeat B-Scan and measurement for added accuracy.



Headquarters

82 Gilbert Street
 Adelaide, SA, 5000 AUSTRALIA
 +61 8 8104 5200

Japan

4-3-7 Miyahara 4F, Yodogawa-ku
 Osaka 532-0003 JAPAN
 +81 6 6396 2250

USA

7138 Shady Oak Road
 Minneapolis, MN, 55344 USA
 1 800 824 7444

Europe Support Center

108, avenue Marx Dormoy
 63000 Clermont-Ferrand FRANCE
 +33 4 73 34 18 55