

OBSERVATION

Treatment of Traumatic Tattoos With the Q-Switched Neodymium:YAG Laser

Harue Suzuki, MD

Background: Treatment for traumatic tattoos often results in incomplete removal of the pigment or produces unacceptable scars or textural changes. Successful results using Q-switched ruby lasers have been reported. The Q-switched neodymium:YAG laser, with a wavelength of 1064 nm and a pulse duration of 5 to 7 nanoseconds, penetrates deeper into the skin and has less interaction with melanin than the Q-switched ruby laser.

Observations: The present study documents 32 cases of traumatic tattoos involving 51 sites of the face, trunk, and extremities in patients ranging in age from 6 to 58 years. All patients were treated with the Q-switched neo-

dymium:YAG laser. Excellent results were noted for 50 of 51 treated tattoos. The number of treatments to achieve excellent results ranged from 1 to 6, with an average of 1.7. No scarring, atrophy, textural changes, or hypopigmentation was noted in any of the cases. Transient postinflammatory hyperpigmentation of 3 months' duration was noted in 1 patient.

Conclusion: The Q-switched neodymium:YAG laser was effective in removing traumatic tattoos without any significant side effects.

Arch Dermatol. 1996;132:1226-1229

TRAUMATIC tattooing results from mechanical penetration of the skin by foreign-body particles associated mostly with abrasive and sometimes with explosive trauma.^{1,2} Another cause is accidental penetration of a pointed pencil tip into the skin. Abrasive traumatic tattoos result when the upper skin layers are removed by friction and foreign pigmented particles are forced into the wound, followed by reepithelialization of the wound without removal of the foreign matter. Abrasive traumatic tattoos are most frequently caused by accidental falls on blacktop surfaces during traffic accidents. Accidents involving fireworks are the most common cause of explosive traumatic tattoos. Fine particles can be embedded quite deeply in these cases.

Immediate, complete removal of the foreign pigmented particles has been the best treatment for the traumatic tattoo,¹⁻⁴ because once the wound has reepithelialized, there has been no way to approach the unwanted foreign particle without destroying the overlying and surrounding tissue. Various treatments, including surgical excision, dermabrasion, salabrasion, use of caus-

tic chemicals, cryosurgery, electrosurgery, and argon and carbon dioxide lasers,² have been tried. These treatments often result in incomplete removal of the pigment or produce an unacceptable degree of scarring or change of skin texture.

Successful removal of traumatic tattoos has been reported using the Q-switched ruby laser without producing any scars but often followed by transient hypopigmentation.^{5,6} The successful use of the alexandrite laser for the treatment of traumatic tattoos has also been described.⁷ The Q-switched neodymium:YAG (Nd:YAG) laser has a longer wavelength than the Q-switched ruby laser, which allows deeper penetration and less interaction with melanin, and, thus, it has been reported to remove decorative tattoos more effectively.⁸ This report describes the results in 32 patients who had traumatic tattoos treated with the Q-switched Nd:YAG laser.

From the Department of Plastic Surgery, Johoku Hospital, Kyoto, Japan.

See Patients and Methods on next page

PATIENTS AND METHODS

Over a period of 30 months, 37 patients with 58 traumatic tattoos who presented to the Department of Plastic Surgery of Johoku Hospital, Kyoto, Japan, were enrolled in this study. Twenty-nine patients were female and 8 were male. All of the patients were Asian. The age of the patients ranged from 6 to 58 years. Fifty-four of the tattoos were caused by abrasion, 1 by explosion, and 3 by pointed pencil trauma. Anatomic areas included the face, extremities, and clavicular region. Informed consent was obtained from the patients after the nature of the procedure had been fully explained. One 6-year-old girl who suffered extensive traumatic tattoos on the face and the clavicular region received general anesthesia and was treated on an outpatient basis. All the other patients were treated with no anesthesia, with local anesthesia using 1% lidocaine with epinephrine, or with an occlusive dressing technique using 7% lidocaine cream.

The Q-switched Nd:YAG laser (Medlite, Continuum Biomedical, Livermore, Calif) was operated at 1064 nm with a pulse width of 5 to 7 nanoseconds using a 3-mm spot and a repetition rate of 10 Hz. There was no significant overlapping. To avoid scarring and textural changes, the lowest-energy fluence that produced immediate whitening of the treated site was used. The laser energy fluence, which was confirmed with a laser pulse energy meter (Nova, Ophir Optronics Ltd, Jerusalem, Israel), ranged from 3 to 8 J/cm². Tattoos with less pigment needed higher-energy fluence and those with darker pigment needed lower-energy fluence to show immediate whitening. A silicone-coated lead shield was placed over the ocular globe when the eyelids were treated. Postoperative wounds were dressed with a topical steroid ointment

with antibiotics for 2 days for relief of pain and inflammation and with a topical antibacterial ointment for the succeeding 3 to 5 days. Wounds on the body and extremities and larger treatment sites on the face were covered with nonadherent dressing. The treated area, which showed immediate whitening, developed epidermal sloughing with slight crusting and healed within 5 to 7 days. Patients were instructed to avoid excessive sun exposure and to use adequate sun protection with clothing and sunscreens for at least 3 months after treatment to prevent hyperpigmentation. They were asked to return for follow-up in 6 to 8 weeks, and additional treatments were performed if fading of the tattoo was incomplete.

Photographs were taken under standardized conditions of all treated sites before each treatment session and 6 months after the final treatment session. The photographs were then evaluated by 3 physicians and 2 nurses. Pretreatment and posttreatment photographs were projected simultaneously, the degree of lightening was determined, and the results for each case were ranked by each observer independently into 1 of 4 categories: excellent, lightened, unchanged, and worsened. Tattoos that were no longer recognizable in the post-treatment photographs were evaluated as excellent. Tattoos that were lightened but still recognizable were evaluated as lightened. Hypopigmentation and hyperpigmentation, textural changes, and scarring were observed and noted as absent or present. Before the experimental data were evaluated, a short series of slides of patients not in this study were shown as a training set. Using this slide set, consensus was reached among the evaluators with respect to the grading system for blue-black pigment lightening. If the evaluation of a particular slide was not unanimous, the category chosen by the largest number of the 5 observers was used as the final assessment.

RESULTS

Results are presented in the **Table**. Two patients, including 1 whose tattoo was caused by explosive trauma, were still being treated at the time of this report. Three patients were unavailable for follow-up. Thirty-two patients with 51 tattoos were followed up for more than 6 months after their final treatment. Of the 51 tattoos, 49 were caused by abrasive trauma and 2 by pointed pencils.

Fifty of 51 tattoos, including the 2 caused by pointed pencils, were evaluated as having an excellent response, with an average of 1.7 treatments. Forty-two tattoos did not show any trace of pigment when examined postoperatively (Table). One tattoo caused by abrasive trauma was assessed as lightened, but the patient was satisfied with the result and did not request further treatment. All anatomic areas, including the face, trunk, and extremities, were effectively treated. No treatment differences were seen related to the cause or anatomic site of the tattoo. Scarring, hypopigmentation, or textural changes were not observed. Transient hyperpigmentation lasting 3 months occurred in 1 case.

Results of Treatment of Traumatic Tattoos With a Q-Switched Neodymium:YAG Laser

No. of Treatments	No. of Tattoos				Total
	Excellent (Completely Cleared)	Lightened	Unchanged	Worsened	
1	27 (26)	0	0	0	27
2	17 (13)	1	0	0	18
3	3 (2)	0	0	0	3
4	2 (1)	0	0	0	2
5	0	0	0	0	0
6	1 (0)	0	0	0	1
Total	50 (42)	1	0	0	51

REPORT OF CASES

CASE 1

A 21-year-old man had traumatic tattoos on his right cheek and chin from a motorcycle accident on asphalt that had occurred 6 months earlier (**Figure 1**, left). A

Q-switched Nd:YAG laser operated at 1064 nm with a pulse width of 5 to 7 nanoseconds, spot diameter of 3 mm, pulse repetition rate of 10 Hz, and fluence of 5 J/cm² was used to attempt to remove the tattoos. Complete removal of the tattoo on the cheek and partial removal of that on the chin were noted 6 weeks after the first treatment. Complete removal of the tattoo on

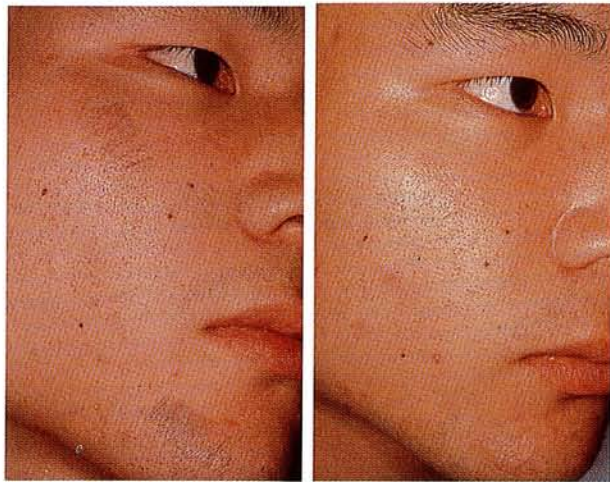


Figure 1. Case 1. Traumatic tattoos from a motorcycle accident on the right cheek and chin of a 21-year-old man. Left, Before treatment. Right, After 1 treatment on the cheek and 2 treatments on the chin with the Q-switched neodymium:YAG laser, the tattoos have completely cleared.

the chin was achieved with an additional treatment performed at the same fluence using the same laser system (Figure 1, right).

CASE 2

An 11-year-old girl presented for removal of a traumatic tattoo on her upper lip of 3 years' duration caused by a car accident. She had been absent from school for 3 months because her classmates were teasing her about her tattoo (**Figure 2**, left). The tattoo was removed by 2 treatments with a Q-switched Nd:YAG laser operated at a fluence of 4.5 to 5.5 J/cm² (Figure 2, right).

CASE 3

A 47-year-old woman presented for removal of a 5-month-old traumatic tattoo on her upper lip caused by a car accident (**Figure 3**, left). Six months after 1 treatment with a Q-switched Nd:YAG laser at a fluence of 6 J/cm², the tattoo was gone, and the textural quality of the treated area had also improved (Figure 3, right).

COMMENT

This report documents the effective use of the Q-switched Nd:YAG laser in the treatment of traumatic tat-

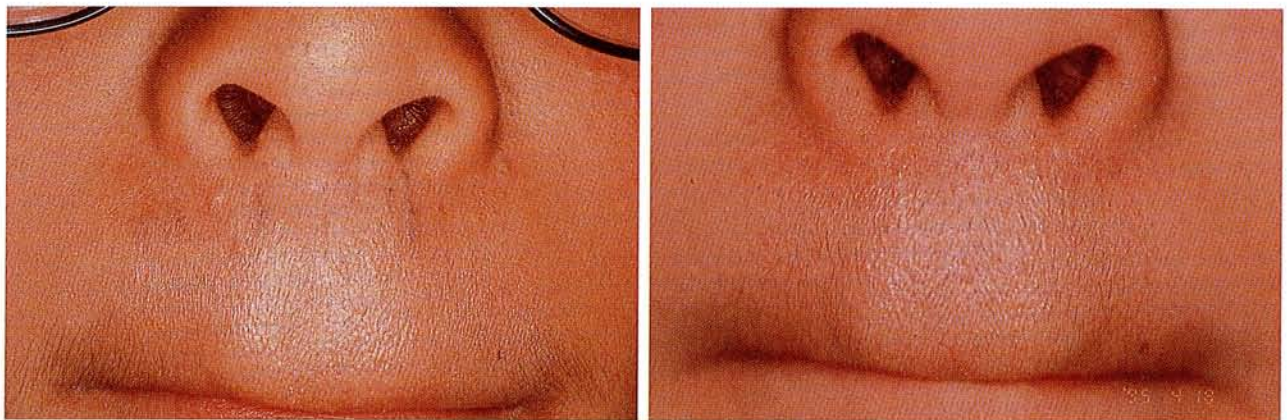


Figure 2. Case 2. A traumatic tattoo from a car accident on the upper lip of an 11-year-old girl. Left, Before treatment. Right, After 2 treatments with the Q-switched neodymium:YAG laser, the tattoo has completely cleared.

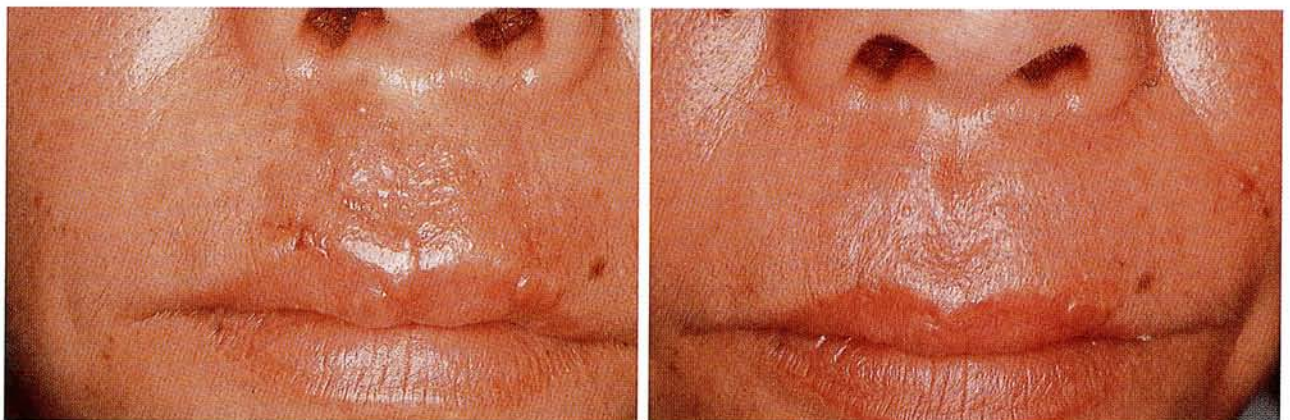


Figure 3. Case 3. A traumatic tattoo from a car accident on the upper lip of a 47-year-old woman. Left, Before treatment. Right, After 1 treatment with the Q-switched neodymium:YAG laser, the tattoo has almost cleared.

toos. The Q-switched Nd:YAG laser removes traumatic tattoos without the undesirable side effects of scarring, textural change, or permanent pigmentary changes that often occur with therapies such as dermabrasion or carbon dioxide laser abrasion.

By choosing a laser device with a wavelength that is well absorbed by the target and not by the surrounding tissues and by using a very short pulse duration, the target will be destroyed selectively while preventing the spread of thermal injury and thus minimizing thermal damage to the adjacent structures.

Successful treatment of traumatic tattoos it has been reported using the Q-switched ruby laser and the alexandrite laser.⁵⁻⁷ The Q-switched Nd:YAG laser, with a wavelength of 1064 nm, was used in this study because it penetrates deeper into the skin and is well absorbed by carbon or graphite, which is presumed to be the major component of traumatic tattoos,^{2,3} yet it has much less melanin absorption than the 694-nm wavelength of the Q-switched ruby laser. Less interaction with melanin is important both to minimize the competition for energy absorption and to lessen the chance that pigmentary changes will occur. Hypopigmentation was not seen in any of the cases in this study, while transient hypopigmentation has often been reported in traumatic and decorative tattoos and nevi of Ota treated with the Q-switched ruby laser.^{6,8-12} This is particularly important when treating pigmentary disorders in Asian skin, with its epidermis rich in melanin. The Q-switched Nd:YAG laser has a high peak power (35 MW) and a very short pulse duration (5-7 nanoseconds). The short pulse duration may have been a factor in the absence of scarring or textural changes in this study. Compared with other lasers, the high peak power of the Nd:YAG laser may cause fragmentation of a greater number of foreign-body particles in 1 treatment or may cause fragmentation into smaller pieces, thus contributing to the fact that the traumatic tattoos were treated effectively with a small

number of treatments (average, 1.7 treatments). The small average number of treatments in this study compared with the number required for decorative tattoos may be associated with the smaller amount of pigment in traumatic tattoos caused by abrasive trauma.

Based on the results of this study, the Q-switched Nd:YAG laser is very effective and safe for the treatment of traumatic tattoos.

Accepted for publication June 3, 1996.

Reprints: Harue Suzuki, MD, Department of Plastic Surgery, Johoku Hospital, 99 Iwakakichi-cho, Kamigamo, Kitaku, Kyoto 603, Japan.

REFERENCES

1. Agris JDDS. Traumatic tattooing. *J Trauma*. 1976;16:798-802.
2. Apfelberg DB, Manchester GH. Decorative and traumatic tattoo biophysics and removal. *Clin Plast Surg*. 1987;14:243-251.
3. Furnas DW, Somers G. Microsurgery in the prevention of traumatic tattoos. *Plast Reconstr Surg*. 1976;58:631-633.
4. Horowitz J, Nichter LS, Stark D. Dermabrasion of traumatic tattoos: simple, inexpensive, effective. *Ann Plast Surg*. 1988;21:257-259.
5. Ashinoff R, Geronemus RG. Rapid response of traumatic and medical tattoos to treatment with the Q-switched ruby laser. *Plast Reconstr Surg*. 1993;91:841-845.
6. Achauer BM, Nelson JS, Vander Kam VM, Applebaum R. Treatment of traumatic tattoos by Q-switched ruby laser. *Plast Reconstr Surg*. 1994;93:318-323.
7. Alster TS. Successful elimination of traumatic tattoos by the Q-switched alexandrite (755-nm) laser. *Ann Plast Surg*. 1995;34:542-545.
8. Kilmer SL, Lee MS, Grevelink JM, Flotte TJ, Anderson RR. The Q-switched Nd:YAG laser effectively treats tattoos. *Arch Dermatol*. 1993;129:971-978.
9. Kilmer SL, Anderson RR. Clinical use of the Q-switched ruby and the Q-switched Nd:YAG (1064 nm and 532 nm) lasers for treatment of tattoos. *J Dermatol Surg Oncol*. 1993;19:330-338.
10. Taylor CR, Gange RW, Dover JS, et al. Treatment of tattoos by Q-switched ruby laser: dose-response study. *Arch Dermatol*. 1990;126:893-899.
11. Geronemus RG. Q-switched ruby laser therapy of nevus of Ota. *Arch Dermatol*. 1992;128:1618-1622.
12. Levine VJ, Geronemus RG. Tattoo removal with the Q-switched ruby laser and the Q-switched Nd:YAG laser: a comparative study. *Cutis*. 1995;55:291-296.